

CASE REPORT

PEER REVIEWED | OPEN ACCESS

Local resection of a pancreatic GIST in the area of the pancreatoduodenal groove. Is the surgical technique a prognostic factor?

Camilo J Castellón Pavón, Gustavo A Díaz García,
Pedro López Fernández, Bairon Alfonso Paz Fernández,
Sonia Morales Artero, Manuel Durán Poveda

ABSTRACT

Introduction: Pancreatic gastrointestinal stromal tumors (GISTs) are exceptional. Preoperative diagnosis is difficult, so only the size is useful to determine the possible biological behavior of the tumor. Although surgery is the definitive treatment, the surgical technique is controversial, especially in those tumors located in the area of the pancreatoduodenal groove.

Case Report: We present a case of a 50-year-old woman who complained of abdominal pain. With the diagnostic imaging techniques, a neuroendocrine tumor was suspected at the level of the pancreatoduodenal groove with liver metastases. The patient was treated by radiofrequency of the hepatic lesions and local

resection of the pancreatic tumor with a Roux-en-Y duodenojejunostomy. The histological study confirmed the diagnosis of low-risk GIST with spindle cells, so the patient did not receive imatinib. After 11 months of follow-up the patients remained asymptomatic and without signs of recurrent disease.

Conclusion: The main determinants of malignancy for GISTs are tumor size and mitotic index. Surgery is the only curative therapy, although the choice of the most optimal technique to treat pancreatic head GIST is controversial. Nineteen cases published have been reviewed and the influence of the surgical technique on survival has been analyzed. Pancreatoduodenectomy (PD) is the most common procedure performed. Local resection is a safe option provided a complete tumor removal with clear surgical margins is guaranteed. The extension of the surgical resection of pancreatic head GISTs has no statistical significant influence in disease-free survival. The preoperative determining factors for deciding the extension of the resection in pancreatic head GISTs are the size and anatomical relationship with the duodenum and the papilla. Different surgical procedures are suggested depending on the anatomic location.

Keywords: Diagnosis, Extragastrointestinal stromal tumor, Pancreas, Pancreatic neoplasms, Pancreatectomy

How to cite this article

Castellón CJ, Díaz GA, López P, Paz BA, Morales S, Durán M. Local resection of a pancreatic GIST in the area of the pancreatoduodenal groove. Is the surgical technique a prognostic factor? J Case Rep Images Surg 2020;6:100080Z12CC2020.

Article ID: 100080Z12CC2020

Camilo J Castellón Pavón¹, PhD, Gustavo A Díaz García², MD, Pedro López Fernández², PhD, Bairon Alfonso Paz Fernández³, MD, Sonia Morales Artero⁴, MD, Manuel Durán Poveda⁵, PhD

Affiliations: ¹Associate Chief, Department of General Surgery, Hospital "Rey Juan Carlos", Rey Juan Carlos University, Móstoles, Madrid, Spain; ²Medical Area Specialist in General Surgery, Department of General Surgery, Hospital "Rey Juan Carlos", Móstoles, Madrid, Spain; ³Department of Pathology, Hospital "Rey Juan Carlos", Móstoles, Madrid, Spain; ⁴Medical Area Specialist in General Surgery, Department of General Surgery, Hospital "El Escorial", San Lorenzo de El Escorial, Madrid, Spain; ⁵Chief of Department, General Surgery, Hospital "Rey Juan Carlos", Rey Juan Carlos University, Móstoles, Madrid, Spain.

Corresponding Author: Camilo J Castellón Pavón, PhD, Associate Chief, Department of General Surgery, Hospital "Rey Juan Carlos", Rey Juan Carlos University, C/ Gladiolo s/n. 28933, Móstoles, Madrid, Spain; Email: camiloj.castellon@quironsalud.es

Received: 21 September 2020

Accepted: 19 October 2020

Published: 16 November 2020

INTRODUCTION

Gastrointestinal stromal tumors (GISTs) are very rare. Although they are the most common mesenchymal tumors of the alimentary tract they only account for 1–2% of malignant gastrointestinal tumors [1]. The most common locations of GISTs are the stomach (50–60%), small intestine (30–35%), and colorectum (5%) [1]. Extragastrintestinal GISTs (E-GISTs) are usually located in the mesentery, retroperitoneum, omentum, and pancreas [1, 2]. The most common anatomic location of pancreatic GISTs (P-GISTs) is the head [1]. Preoperative diagnosis of P-GISTs is difficult because almost half show a heterogeneous appearance with a cystic component in radiological studies and their hypervascular behavior makes differentiation with pancreatic neuroendocrine tumors (PNET) difficult [1, 3]. The treatment of P-GISTs depends mainly on the anatomical location in the pancreas, with extended resections and lymphadenectomy being unnecessary. We present a case localized in the area of the pancreatoduodenal groove treated with local resection and the literature is reviewed to analyze the prognostic influence of the surgical technique performed to treat GISTs of the pancreatic head and uncinate process.

CASE REPORT

A 50-year-old woman, with no history of interest, reported weight loss and occasional abdominal pain in the right upper quadrant. Laboratory test parameters were normal and ultrasound showed a solid hypoechoic lesion of 30 × 35 × 31 mm, in the hepatic hilum, which could be an adenopathy or pancreatic head tumor. A contrast-enhanced computed tomography (CT) scan confirmed the presence of a tumor measuring 39 × 61 × 35 mm at the level of the pancreatoduodenal groove, with a heterogeneous attenuation pattern and enhancement in the arterial phase with areas of central necrosis. The rest of the pancreas was normal without focal lesions or dilation of the main duct. There were no radiological criteria for locoregional lymph node involvement. There were also two enhancing liver lesions in arterial phase in segments IVa (7 mm) and VII (26 mm), isodense with the liver parenchyma in portal phase, suspicious of secondary deposits of a hypervascular lesion, all compatible with metastatic PNET. In magnetic resonance imaging (MRI) the findings were similar, although in SPECT the possibility of benign lesions (focal nodular hyperplasia) cannot be ruled out. A core needle biopsy of the segment VII lesion was performed without showing malignancy. Upper GI endoscopy showed erosive gastritis and a suggestive image of extrinsic compression at the duodenal bulb. There were no signs of malignancy in the biopsies

performed on the gastric body, antrum, and duodenum.

Endoscopic ultrasound showed a well-defined, hypervascularized, heterogeneous, and hypoechoic lesion of 4 cm in diameter, suggestive of PNET. Fine needle aspiration (FNA) cytology was performed where scarce cellularity was observed with neuroendocrine cells without cytological atypia.

Elective surgery was performed, and a pseudo-encapsulated tumor was found close to the pancreatoduodenal groove at the second duodenal portion, approximately 4 cm in diameter, with an exophytic component. In the rest of the abdominal exploration, no peritoneal implants or palpable liver lesions were observed. Intraoperative ultrasound showed that the lesion was separated from the Wirsung and confirmed the existence of three liver lesions of 2.7 cm in segment VII, 1.5 cm in segment IVa, and another of 1 cm in segment I. Radioablation of the three lesions is performed, followed by Kocher's maneuver, cholecystectomy, and introduction of a Fogarty catheter. Through an anterior duodenotomy it is confirmed that the papilla is distal to the lesion. Because of these findings and with the suspicion of a PNET, it is decided to perform a local resection including pancreatic parenchyma and section of the duodenum at 2 cm from the pylorus with wide safety margins and closure of the distal duodenum with endostapler, preserving the papilla. The intervention is completed with a Roux-en-Y duodenojejunostomy, without local lymphadenectomy. The macroscopic histological study shows a tumor of 3.5 × 2.8 × 2 cm with pancreatic and duodenal tissue. Microscopically the findings are compatible with an encapsulated P-GIST, with spindle cells (Figure 1), without necrosis, 4 mitosis/50 high power fields (HPF) (low risk), without the involvement of borders neither of four peripancreatic nodes examined (pT2, No, AJCC 8th edition). The lesion shows positivity for the immunohistochemical technique of CD 117 (Ckit), actin, and DOG1 and negativity for desmin, S100, HMB45, EMA, CD34, CD31, chromogranin, and synaptophysin. Ki65 is less than 2%.

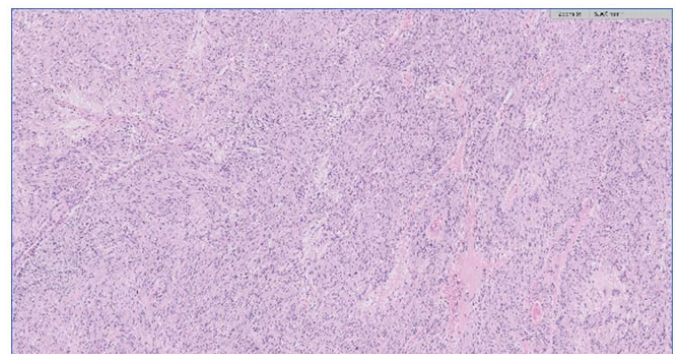


Figure 1: Hematoxylin and eosin staining (×5): It is identified a lesion composed by slightly intercrossed beams of predominantly spindle cells, with elongated nuclei and blunt ends, without increased atypia or mitosis.

The postoperative period includes a prolonged hospital stay due to a duodenal stump fistula that required surgical reintervention (Grade IIIb of Clavien's classification). The patient did not receive adjuvant treatment with imatinib and after 11 months of follow-up is asymptomatic with no signs of recurrence or liver lesions on the control CT scan.

DISCUSSION

Gastrointestinal stromal tumors are rare tumors and account for only 1–2% of malignant gastrointestinal tumors [1]. The most frequent locations are the stomach (50–60%), small intestine (30–35%), and colorectum (5%) with only 4% being duodenal GISTs (D-GISTs) [1, 4]. The main prognostic factors are the size, location, surgical resection margins, intraoperative tumor rupture, and mitotic index [1, 3, 5, 7]. Extragastrointestinal GISTs only represent 5–10% of GISTs, although they have a worse prognosis than gastric GISTs (G-GISTs) [2, 6]. The treatment of choice for any potentially resectable GIST ≥ 2 cm without liver metastases is surgery, and there is currently a consensus on the role of imatinib in adjuvant therapy in patients with higher risk of relapse [3, 7–9].

Pancreatic GISTs are exceptional, with a small number of published cases, short postoperative follow-ups, and no conclusive evidence on their biological behavior or prognostic differences according to the anatomical location in the pancreas. Liu et al. have conducted the only comparative study between G-GISTs and P-GISTs, being P-GISTs larger and more malignant [1]. The disease-free interval (DFS) has been lower than in G-GISTs, although there has been no difference in disease-related survival [1].

In a review of the literature we found, including our case, a total of 51 P-GIST. The most frequent location has been the pancreatic head in 22 cases (43.1%) (three tumors in the uncinate process and two in the head-body). Of these, we have analyzed 19 GISTs of the pancreatic head and uncinate process after excluding two cases in which the surgical treatment was not specified and another because it was mainly body involvement with extension to the head (Table 1) [10–12]. There were no differences in sex (10 women and 9 men), the mean age was 50.2 years (31–70) and the mean size of the tumor was 6.8 cm (1.5–24). Most pancreatic head GISTs are symptomatic. Abdominal pain is the most frequent symptom (68.4%) and 36.8% patients have anemia. Despite the large size of the lesions, no patient presented obstructive jaundice. Preoperative diagnosis is difficult to make and only in three cases (15.7%) was the diagnosis of P-GIST confirmed by a FNA [13–15]. The preoperative diagnosis was cystic tumor in five patients (26.3%) and PNET in four other cases (21%). Most were spindle cell type (94.4%) and 77% showed an intermediate or high-risk category. Pancreatoduodenectomy was performed in 14 patients (10 Whipple and 4 with pyloric preservation). In five cases (26.3%) the surgical technique was more limited:

three enucleations and two wedge local resections, with one pancreatico-jejunostomy and a duodenojejunostomy in our case. Eight patients received adjuvant treatment with imatinib, all of them after PD. Four patients (all with high-risk GIST) developed liver metastases: three after PD and imatinib, and one after local resection without adjuvant therapy.

Numerous pathologies have been described at the pancreatoduodenal groove. Preoperatively it is difficult to differentiate a P-GIST from a PNET or other cystic tumors of the pancreas. Endoscopic ultrasound is the best diagnostic technique to determine the exact location by differentiating between a pancreatic or duodenal tumor adjacent to the pancreas [1]. In P-GISTs the surgical treatment will depend on the location, although extensive resections and lymph node dissection are unnecessary. Pancreatoduodenectomy with or without pyloric preservation is the most commonly used technique in pancreatic head GISTs (73.6%), while local resection is more frequent in D-GISTs (62–70.8%) [4, 16, 17]. In D-GISTs, PD has been used in larger lesions (76% in lesions ≥ 5 cm) and located in the second duodenal portion (64.3–81%), although it has had higher rates of recurrence than local resection because it has been performed on more biologically malignant tumors [4, 16, 17]. Although PD is a safe technique in the treatment of pancreatic head tumors, it is not exempt from significant morbidity and mortality [16, 18]. Local resections of P-GISTs are less surgical time consuming, allow preservation of pancreatic function and have fewer postoperative complications [4, 7, 16]. The main determining factors for local resection are the general condition of the patient, preoperative diagnosis of PNET, invasion of adjacent structures, size and location [3, 16]. The margins of resection are not clearly established, but it is recommended that they be 1–2 cm [4, 16]. Intraoperative ultrasound must ensure that the lesion is sufficiently separated from the Wirsung before indicating an enucleation. When the GIST is located at the level of the pancreatoduodenal groove the choice of technique is controversial [4].

Of the 19 GISTs in the pancreatic head reviewed, the DFS has been analyzed using the Kaplan–Meier method and the log-rank test (Mantel–Cox), considering a statistically significant $p < 0.05$. We found no statistically significant differences in DFS when analyzing sex ($p = 0.07$), age ($>$ or < 60 years, $p = 0.64$), type of surgical technique ($p = 0.44$), tumor size ($>$ or < 5 cm, $p = 0.58$) and risk grade ($p = 0.08$). Shen et al. [16] reported a worse prognosis in the group of male patients operated by D-GIST and Lopes et al. reported a significantly higher incidence of androgen receptors in E-GISTs [19]. In our review all recurrences have been in male patients with high-grade GISTs. However, there has been no statistical significance when analyzing both variables, probably because of the small number of cases.

Given the impossibility of knowing the biological behavior of the tumor preoperatively, the main factors for deciding the extension of the surgical resection in

Table 1: Operated GISTs of the pancreatic head and uncinate process

Author (year)	Age (years)	Sex	Clinic	Anemia	Size (cm)	Location	Preoperative diagnosis	Surgical treatment	Mitosis /50 HPF	Risk grade	Cellularity	Imatinib	Follow-up (months)	Complications (Clavien)	Recurrence	Reop.
Daum (2005)	70	F	Incidental	No	10	Head	Cystic tumor	PD	2	I	Spindle	Yes	6	Pancreatic fistula (IIIa)	No	No
Goh (2009)	58	M	Weight loss	No	8.9	Head	Cystic tumor	PD	>10	H	Spindle	No	60	No	No	No
Trabelsi (2009)	52	F	Abdominal pain	No	10.5	Head	Unspecific	PD + segmentary colectomy	6	H	Mixed	No	10	No	No	No
Saif (2010)	31	M	Abdominal pain + UGIB + CS	Yes	8	Head	Unspecific	PP-PD	48	H	Spindle	Yes	9	Retropertitoneal collection (IIIa)	Liver metastases (9 months)	No
Rao (2011)	40	M	Abdominal pain + CS	Yes	6.5	Head-body	GIST (FNA)	PD	8–10	H	Spindle	Yes	30	No	Liver metastases (24 months)	Liver resection
Vij (2011)	35	M	Abdominal pain + weight loss	Yes	6	Head	Adenocarcinoma	PD	12–15	H	Spindle	Yes	24	No	Liver metastases (24 months)	Liver resection
Wegge (2012)	55	M	UGIB	Yes	4.5	Head	Cystic tumor	PD	6	I	Spindle	Yes	NS	Pancreatic fistula (IIIa)	No	No
Babu (2012)	55	F	Abdominal pain	No	5	Head	Unspecific	Local resection + Roux-en-Y PJ	6–8	I	Spindle	No	11	No	No	No
Soufi (2013)	39	M	Abdominal pain + CS	Yes	10	Head	Cystic tumor	PD + segmentary colectomy	<5	I	Spindle	Yes	24	No	No	No
Tian (2014)	60	M	Incidental	No	6	Uncinate process	PNET	Enucleation	>5	H	Spindle	No	36	No	Liver metastases (12 months)	No
Beltrame (2014)	69	F	Abdominal pain	No	2.4	Uncinate process	PNET	Enucleation	1	L	Spindle	No	12	No	No	No
Akbulut (2014)	61	F	Incidental	No	5	Head	Unspecific	PD	NS	L	Spindle	Yes	48	No	No	No
Zhang (2016)	60	F	Abdominal pain	No	3.6	Head	PNET	PD	NS	NS	NS	NS	NS	NS	NS	NS
Kwon (2017)	64	F	Incidental	No	7	Head	GIST (FNA)	PP-PD	5	I	Spindle	No	72	No	No	No
Yeo (2018)	45	F	Abdominal pain	No	6.8	Head-uncinate process	GIST (FNA)	PP-PD	<1	I	Spindle	No	12	No	No	No
Yol (2018)	56	M	Abdominal pain + UGIB	Yes	15	Head	Unspecific	PD	<3	H	Spindle	Yes	NS	No	NS	NS
Tounsi (2018)	49	F	Abdominal pain	No	2.4	Head	Cystic tumor	Enucleation	4	L	Spindle	No	9	No	No	No
Rasool (2018)	60	M	Abdominal pain	Yes	8	Head	Unspecific	PP-PD	<5	I	Spindle	No	NS	NS	NS	NS
Castellón (2020)	50	F	Abdominal pain + weight loss	No	3.5	Head	PNET	Local resection + Roux-en-Y DJ	4	L	Spindle	No	11	Duodenal stump fistula (IIIb)	No	Yes

Abbreviations: M: male; F: female; HPF: high power fields; UGIB: upper gastrointestinal bleeding; CS: constitutional syndrome; NS: not-stated; PD: pancreaticoduodenectomy; PP-PD: pylorus preserving pancreaticoduodenectomy; Reop: reoperation; H: high; I: intermediate; L: low. P1: pancreaticojejunostomy; D1: duodenojejunostomy; FNA: fine needle aspiration; DJ: duodenojejunostomy.

GISTs of the pancreatic head are the size of the tumor and its anatomical relationship with the duodenum and the papilla. In all lesions larger than 5 cm or close to the ampulla of Vater, PD should be performed, and pyloric preservation is recommended [2]. In tumors of the uncinate process <5 cm local resection can be tried. For GISTs of the pancreatic head, if the lesion measures <3 cm, enucleation or local resection with safety margins and partial duodenectomy with primary closure of the duodenal defect can be performed [4]. In tumors among 3–5 cm at the first duodenal portion it would be advisable to associate an antrectomy. If there is sufficient margin, the duodenum near the pylorus can be sectioned, with stapling of the duodenum proximal to the ampulla of Vater, and a Roux-en-Y duodenojejunostomy performed. In those GISTs with involvement of the third duodenal portion, the options for reconstruction after a local resection are a duodeno-duodenostomy or a Roux-en-Y duodeno-jejunostomy [17].

CONCLUSION

In conclusion, the surgical technique does not influence the survival of pancreatic head GISTs. Local resection is oncologically safe, and the preoperative decision depends on the size and location of the tumor. The postoperative histological study will determine the risk of recurrence and the need for adjuvant treatment with imatinib.

REFERENCES

1. Liu Z, Tian Y, Xu G, Liu S, et al. Pancreatic gastrointestinal stromal tumor: Clinicopathologic features and prognosis. *J Clin Gastroenterol* 2017;51(9):850–6.
2. Akbulut S, Yavuz R, Otan E, Hatipoglu S. Pancreatic extragastrointestinal stromal tumor: A case report and comprehensive literature review. *World J Gastrointest Surg* 2014;6(9):175–82.
3. Beltrame V, Gruppo M, Pastorelli D, Pizzi S, Merigliano S, Sperti C. Extra-gastrointestinal stromal tumor of the pancreas: Case report and review of the literature. *World J Surg Oncol* 2014;12:105.
4. Zhou B, Zhang M, Wu J, Yan S, Zhou J, Zheng S. Pancreaticoduodenectomy versus local resection in the treatment of gastrointestinal stromal tumors of the duodenum. *World J Surg Oncol* 2013;11:196.
5. Casali PG, Abecassis N, Aro HT, et al. Gastrointestinal stromal tumours: ESMO-EURACAN clinical practice guidelines for diagnosis, treatment and follow-up. *Ann Oncol* 2018;29(Suppl 4):iv68–78.
6. Yi JH, Park BB, Kang JH, et al. Retrospective analysis of extra-gastrointestinal stromal tumors. *World J Gastroenterol* 2015;21(6):1845–50.
7. Demetri GD, von Mehren M, Antonescu CR, et al. NCCN task force report: Update on the management of patients with gastrointestinal stromal tumors. *J Natl Compr Canc Netw* 2010;8 Suppl 2(0 2):S1–44.

8. Judson I, Bulusu R, Seddon B, Dangoor A, Wong N, Mudan S. UK clinical practice guidelines for the management of gastrointestinal stroma tumours (GIST). *Clin Sarcoma Res* 2017;7:6.
9. Joensuu H. Risk stratification of patients diagnosed with gastrointestinal stromal tumor. *Hum Pathol* 2008;39(10):1411–9.
10. Meng L, Fang SH, Jin M. An unusual case of pancreatic and gastric neoplasms (2010:12b): Malignant GISTs originating from the pancreas and stomach. *Eur Radiol* 2011;21(3):663–5.
11. Yan BM, Pai RK, Dam JV. Diagnosis of pancreatic gastrointestinal stromal tumor by EUS guided FNA. *JOP* 2008;9(2):192–96.
12. Krska Z, Pesková M, Povýsil C, Horejs J, Sedláčková E, Kudrnová Z. GIST of pancreas. *Prague Med Rep* 2005;106(2):201–8.
13. Rao RN, Vij M, Singla N, Kumar A. Malignant pancreatic extra-gastrointestinal stromal tumor diagnosed by ultrasound guided fine needle aspiration cytology. A case report with a review of the literature. *JOP* 2011;12(3):283–6.
14. Kwon HJ. Extra-gastrointestinal stromal tumor of the pancreas: Report of a case. *Ann Hepatobiliary Pancreat Surg* 2017;21(4):237–42.
15. Yeo SJ, Cho CM, Kwon HJ, et al. An extragastrointestinal stromal tumor originating from the pancreas. *Case Rep Gastroenterol* 2018;12(3):671–8.
16. Shen Z, Chen P, Du N, Khadaroo PA, Mao D, Gu L. Pancreaticoduodenectomy versus limited resection for duodenal gastrointestinal stromal tumors: A systematic review and meta-analysis. *BMC Surg* 2019;19(1):121.
17. Lee SY, Goh BKP, Sadot E, et al. Surgical strategy and outcomes in duodenal gastrointestinal stromal tumor. *Ann Surg Oncol* 2017;24(1):202–10.
18. Nimptsch U, Krautz C, Weber GF, Mansky T, Grützmann R. Nationwide in-hospital mortality following pancreatic surgery in Germany is higher than anticipated. *Ann Surg* 2016;264(6):1082–90.
19. Lopes LF, Bacchi CE. Androgen receptor expression in gastrointestinal stromal tumor. *Appl Immunohistochem Mol Morphol* 2009;17(2):146–50.

Author Contributions

Camilo J Castellón Pavón – Conception of the work, Design of the work, Acquisition of data, Analysis of data, Interpretation of data, Drafting the work, Revising the work critically for important intellectual content, Final approval of the version to be published, Agree to be accountable for all aspects of the work in ensuring that questions related to the accuracy or integrity of any part of the work are appropriately investigated and resolved

Gustavo A Díaz García – Acquisition of data, Interpretation of data, Revising the work critically for important intellectual content, Final approval of the version to be published, Agree to be accountable for all aspects of the work in ensuring that questions related to the accuracy or integrity of any part of the work are appropriately investigated and resolved

Pedro López Fernández – Analysis of data, Interpretation of data, Revising the work critically for important intellectual content, Final approval of the version to be published, Agree to be accountable for all aspects of the work in ensuring that questions related to the accuracy or integrity of any part of the work are appropriately investigated and resolved

Bairon Alfonso Paz Fernández – Acquisition of data, Analysis of data, Interpretation of data, Revising the work critically for important intellectual content, Final approval of the version to be published, Agree to be accountable for all aspects of the work in ensuring that questions related to the accuracy or integrity of any part of the work are appropriately investigated and resolved

Sonia Morales Artero – Analysis of data, Interpretation of data, Revising the work critically for important intellectual content, Final approval of the version to be published, Agree to be accountable for all aspects of the work in ensuring that questions related to the accuracy or integrity of any part of the work are appropriately investigated and resolved

Manuel Durán Poveda – Analysis of data, Interpretation of data, Revising the work critically for important intellectual content, Final approval of the version to be published, Agree to be accountable for all aspects of the work in ensuring that questions related to the accuracy or integrity of any part of the work are appropriately investigated and resolved

Guarantor of Submission

The corresponding author is the guarantor of submission.

Source of Support

None.

Consent Statement

Written informed consent was obtained from the patient for publication of this article.

Conflict of Interest

Authors declare no conflict of interest.

Data Availability

All relevant data are within the paper and its Supporting Information files.

Copyright


© 2020 Camilo J Castellón Pavón et al. This article is distributed under the terms of Creative Commons Attribution License which permits unrestricted use, distribution and reproduction in any medium provided the original author(s) and original publisher are properly credited. Please see the copyright policy on the journal website for more information.

Access full text article on
other devices



Access PDF of article on
other devices





Submit your manuscripts at
www.edoriumjournals.com

