

CASE REPORT

PEER REVIEWED | OPEN ACCESS

# Tenosynovial giant cell tumor: A rare entity

Kaushik Bhattacharya, Somi Dey Sarkar

## ABSTRACT

Tenosynovial giant cell tumors (TGCT) are benign rare tumors involving the synovium, bursae, and tendon sheaths. Though they are benign, they can grow and can damage the neighboring structure. A case report of a 36-year-old male presenting with a 3 cm × 3 cm non-tender irregular nodular swelling over the lateral surface of terminal phalanx of the right index finger is being done which underwent surgery with the final diagnosis of TGCT.

**Keywords:** Bursae, Giant cell tumor, Synovium, Tendon

### How to cite this article

Bhattacharya K, Sarkar SD. Tenosynovial giant cell tumor: A rare entity. J Case Rep Images Surg 2021;7:100094Z12KB2021.

Article ID: 100094Z12KB2021

\*\*\*\*\*

doi: 10.5348/100094Z12KB2021CR

## INTRODUCTION

Tenosynovial giant cell tumors are rare benign tumors involving the joints, bursae, and tendon sheaths. Usually, this tumor involves the digits and wrist and causes restricted mobility of the localized area. The most nagging problem of tenosynovial giant cell tumor is the recurrence after the surgical treatment.

## CASE REPORT

A 36-year-old presented with a non-tender nodular swelling of 3 cm × 3 cm over the lateral surface of terminal phalanx of the right index finger of six months duration which is causing a restricted mobility of the finger (Figure 1). X-ray of the finger did not reveal any abnormality. He underwent surgery under local anesthesia, and the entire nodular growth was excised in toto along with a part of the tendon sheath. The histopathology revealed TGCT. Microscopic examination showed a well encapsulated tumor composed of proliferation of bland polygonal cells with eosinophilic cytoplasm as well as scattered multinucleate giant cells. Few areas showed collection of foamy macrophages and occasional hemosiderin laden macrophages (Figure 2).




Figure 1: Tenosynovial giant cell tumor of right index finger.

Kaushik Bhattacharya<sup>1</sup>, Somi Dey Sarkar<sup>2</sup>

**Affiliations:** <sup>1</sup>MS DNB MNAMS FAIS FACS FRCS (Glasgow) FRCS (Edin), Specialist Surgery, CAPFs Composite Hospital BSF Kadamtala, Siliguri, West Bengal 734011, India; <sup>2</sup>MD (Pathology), Commandant/CMO (SG), CAPFs Composite Hospital BSF Kadamtala, Siliguri, West Bengal 73401, India.

**Corresponding Author:** Dr. Kaushik Bhattacharya, G616, Uttorayon, Matigara, Siliguri 734010, West Bengal, India; Emailkbhattacharya10@yahoo.com

Received: 15 June 2021

Accepted: 17 August 2021

Published: 08 September 2021

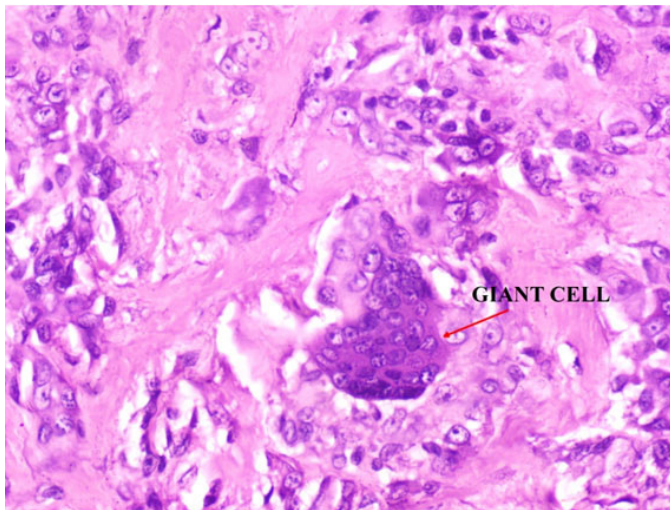


Figure 2: Histopathology shows giant cell in the tumor.

## DISCUSSION

Tenosynovial giant cell tumors (TGCTs) are extremely rare, locally aggressive but benign neoplasms of joints, bursae, and tendon sheaths. Localized TGCTs mainly involve the digits and wrist (85% of cases); foot and ankle, knee, hip, or other joint locations are rarer. Diffuse forms mainly involve the large joints: knee, hip, ankle, and elbow. Tenosynovial giant cell tumor is a rare pathology (incidence, 1/1,800,000) which affects young subjects in the 4th and 5th decades of life. In 2013, the World Health Organization classified these lesions as two distinct types of giant cell tumor: giant cell tumor of the tendon sheath and pigmented villonodular synovitis (PVNS) [1]. There is a chromosomal translocation in a small number of cases of TGCT. In these tumors, there is a translocation involving specific regions on chromosome 1 and chromosome 2. This is written as  $t(1;2)(p13;q37)$ . Preop biopsy has not been used to diagnose TGCTs because surgery was the only treatment option; however, with the advent of a systemic treatment, a synovial biopsy may be helpful. Positron emission tomography (PET) with fluorine-18 fluorodeoxyglucose with computed tomography (FDG PET/CT) is recommended to differentiate malignant from benign TGCT tumors and also to detect distant metastasis. The characteristic histopathology consists of mononuclear cells with multinucleated giant cell and variable pigment laden macrophages. The most important confusion on histopathology happens with other pathologies are sarcoidosis, melanoma, fibrous histiocytoma, and eumycetoma. Ladybird cell is the pathognomonic feature in histopathology of TGCT, while surgery is the mainstay of treatment. Surgery for localized TGCT tends to be curative. However, there is a risk of recurrence around 15–30%. Tenosynovial giant cell tumor is typically treated with synovectomy, removing the involved area of the lining. Radiation therapy has been used as an adjunct treatment to surgery,

particularly in cases where there is incomplete resection of the tumor. The FDA approved pexidartinib (Turalio), the first systemic treatment for patients with TGCTs that demonstrated a robust tumor response in 2019. Turalio showed over 50% response in TGCT patients with 39% of TGCT patients having partial response and 18% having complete response [2]. Targeted therapies are presently underevaluation, which are isotopic synoviorthesis and external radiation therapy. Dealing with a recurrent TGCT may be a nuisance [3]. Although gross radical resection with negative margins is not necessary in the majority of cases [4], however for the patients with unresectable disease or multiple recurrences, systemic therapy using CSF1R inhibitors may postpone the surgery and improve functional outcomes [5]. The first case of malignant TGCT was described by Castens et al. [6] in 1979 on a 48-year-old woman with a sarcoma arising from a pre-existing TGCT of the foot. Wang et al. were the first to report about TSGCT of the spine in 1980. [7], and approximately 80 cases have since been reported. The most common site of TGCT was the cervical spine, followed by the lumbar and thoracic spines. Among the cervical spine, the tumor involves mostly the lower cervical vertebrae and pathogenesis start from the facet joint synovium. The recurrence rates after gross total resection and subtotal resection were 6.7% and 66.7%, respectively, with recurrence happening due to incomplete clearance during resection [8]. Though the effects of potent CSF1R inhibitors are still experimental in the management of malignant TGCT, but conventional cytotoxic chemotherapy may also be considered as part of the treatment strategy of metastatic disease [9]. It has been reported in the literature that TGCT has been detected in few extremely rare locations, like the retropharynx. In such cases, TGCT is often not included among the differential diagnoses because of the rarity of its occurrence and this confusion in diagnosis leads to delay in treatment [10]. The differential diagnosis which every surgeon should keep in mind while dealing with a case of TGCT are the ganglion cyst, pigmented villonodular synovitis, desmoid tumors, fibroma of the tendon sheath, fibrosarcoma, rheumatoid arthritis nodules and glomangioma. There is ongoing discussion if the term “malignant tenosynovial germ cell tumour” should be replaced with the terminology—“synovial sarcoma” [11].

## CONCLUSION

The surgeon and the pathologist should work as a team to diagnose and manage a case of tenosynovial giant cell tumor. Any delay in treatment by the surgeon or any type of histopathological misdiagnosis by the pathologist only causes anxiety and confusion in the mind of the patient. With the recurrence rate of 15–30% in the literature, the patient should be prognosticated and made well aware of this complication prior to surgery. In case of malignant

TGCT, the surgeon should also insist of newer modalities of treatment apart from the radical surgical management.

## REFERENCES

1. Healey JH, Bernthal NM, van de Sande M. Management of tenosynovial giant cell tumor: A neoplastic and inflammatory disease. *J Am Acad Orthop Surg Glob Res Rev* 2020;4(11):e20.00028.
2. Giustini N, Bernthal NM, Bukata SV, Singh AS. Tenosynovial giant cell tumor: Case report of a patient effectively treated with pexidartinib (PLX3397) and review of the literature. *Clin Sarcoma Res* 2018;8:14.
3. Haijun T, Yun L, Xinli Z, Zengming X. Treatment of tenosynovial giant-cell tumour types. *Lancet Oncol* 2019;20(8):e398.
4. Martin RC 2nd, Osborne DL, Edwards MJ, Wrightson W, McMasters KM. Giant cell tumor of tendon sheath, tenosynovial giant cell tumor, and pigmented villonodular synovitis: Defining the presentation, surgical therapy and recurrence. *Oncol Rep* 2000;7(2):413–9.
5. Vinod R, Wei-Lien W, Valerae OL. Treatment of tenosynovial giant cell tumor and pigmented villonodular synovitis. *Current Opinion in Oncology* 2011;23(4):361–6.
6. Castens HP, Howell RS. Malignant giant cell tumor of tendon sheath. *Virchows Arch A Pathol Anat Histol* 1979;382(2):237–43.
7. Wang K, Zhu B, Yang S, Liu Z, Yu M, Liu X. Primary diffuse-type tenosynovial giant cell tumor of the spine: A report of 3 cases and systemic review of the literature. *Turk Neurosurg* 2014;24(5):804–13.
8. Furuhashi R, Iwanami A, Tsuji O, et al. Tenosynovial giant cell tumor of the cervical spine: A case report. *Spinal Cord Ser Cases* 2019;5:23.
9. Nakayama R, Jagannathan JP, Ramaiya N, et al. Clinical characteristics and treatment outcomes in six cases of malignant tenosynovial giant cell tumor: Initial experience of molecularly targeted therapy. *BMC Cancer* 2018;18(1):1296.
10. Jung MR, Lee JY, Kim SY. Retropharyngeal tenosynovial giant cell tumor misdiagnosed as oropharyngeal cancer: A case report. *Investig Magn Reson Imaging* 2018;22(4):272–6.
11. Al-Ibraheemi A, Ahrens WA, Fritchie K, et al. Malignant tenosynovial giant cell tumor: The true “synovial sarcoma?” A clinicopathologic, immunohistochemical, and molecular cytogenetic study of 10 cases, supporting origin from synoviocytes. *Mod Pathol* 2019;32(2):242–51.

\*\*\*\*\*

## Author Contributions

Kaushik Bhattacharya – Conception of the work, Design of the work, Acquisition of data, Analysis of data, Drafting the work, Final approval of the version to be published, Agree to be accountable for all aspects of the work in ensuring that questions related to the accuracy or integrity of any part of the work are appropriately investigated and resolved

Somi Dey Sarkar – Design of the work, Interpretation of data, Drafting the work, Revising the work critically for important intellectual content, Final approval of the version to be published, Agree to be accountable for all aspects of the work in ensuring that questions related to the accuracy or integrity of any part of the work are appropriately investigated and resolved

## Guarantor of Submission

The corresponding author is the guarantor of submission.

## Source of Support

None.

## Consent Statement

Written informed consent was obtained from the patient for publication of this article.

## Conflict of Interest

Authors declare no conflict of interest.

## Data Availability

All relevant data are within the paper and its Supporting Information files.

## Copyright

© 2021 Kaushik Bhattacharya et al. This article is distributed under the terms of Creative Commons Attribution License which permits unrestricted use, distribution and reproduction in any medium provided the original author(s) and original publisher are properly credited. Please see the copyright policy on the journal website for more information.

Access full text article on  
other devices



Access PDF of article on  
other devices





