CASE REPORT PEER REVIEWED | OPEN ACCESS

Ectopic bile duct: A case report and brief review

Xin Yi Goai, Michelle Min Hsiao, Mohamed Ashour

ABSTRACT

Introduction: An ectopic bile duct is the confluence of common bile duct (CBD) and main pancreatic duct away from its usual location in the posteromedial wall of the second part of duodenum. This increases risk of choledocholithiasis and pancreatitis, while proximal locations increase risk of duodenal ulceration and stenosis.

Case Report: A woman in her late forties was consented to elective laparoscopic cholecystectomy for symptoms of biliary colic and ultrasonographic features of a mobile gallstone. Intraoperative cholangiogram noted dilated biliary tree and main pancreatic duct despite normal liver function values, as well as an ectopic ampulla of Vater to distal third part of duodenum or proximal fourth part of duodenum. The distal bile duct had a longer common channel. The operation was otherwise uncomplicated. Magnetic resonance cholangiopancreatography demonstrated similar findings. The patient recovered uneventfully and was discharged from surgical services.

Conclusion: The gold standard for diagnosing ectopic bile ducts is via endoscopic retrograde cholangiopancreatography. Hepatobiliary anatomical variants can also occur in the location of the ampulla, thus it is important for surgeons and trainees to interpret and document this carefully during intraoperative cholangiogram, especially in patients who may require endoscopic retrograde cholangiopancreatography in the perioperative period and/or later date. The patient should be educated on the associated risks and red flags to seek medical attention.

Xin Yi Goai[1], Michelle Min Hsiao[2], Mohamed Ashour[3]

Affiliations: [1]MBBS (Hons), General Surgery Registrar, General Surgery Unit, Northern Health, Epping, VIC 3076, Australia; [2]MBBS, Resident Medical Officer, General Surgery Unit, Northern Health, Epping, VIC 3076, Australia; [3]PhD, FRACS, Consultant Surgeon, General Surgery and Hepatopancreaticobiliary Unit, Northern Health, Epping, VIC 3076, Australia.

Corresponding Author: Xin Yi Goai, General Surgery Unit, Northern Health, 185 Cooper St, Epping, VIC 3076, Australia; Email: xy_goai@yahoo.com

Received: 17 April 2023
Accepted: 21 August 2023
Published: 21 September 2023

Keywords: Cholecystectomy, Ectopic ampulla of Vater, Ectopic bile duct, Hepatopancreaticobiliary surgery, Laparoscopic surgery

How to cite this article

Goai XY, Hsiao MM, Ashour M. Ectopic bile duct: A case report and brief review. J Case Rep Images Surg 2023;9(2):7–11.

Article ID: 100122Z12XG2023

****

doi: 10.5348/100122Z12XG2023CR

INTRODUCTION

The hepatopancreatic ampulla of Vater is located at the posteromedial wall of the second part of duodenum (D2). Ectopic ampulla of Vater (EAV) is the confluence of common bile duct (CBD) and main pancreatic duct where there is no usual papillary opening in the posteromedial wall of D2 but instead may arise at the duodenal bulb, and less commonly into third (D3) and fourth (D4) parts of the duodenum, or parts of the stomach [1, 2] (Figure 1). Ectopic ampulla of Vater may cause upper abdominal pain, choledocholithiasis, ascending cholangitis, and acute pancreatitis. As bile drains proximally, duodenal ulceration and stenosis near the opening may develop [2]. Periampullary carcinoma in association with EAV to D4 has also been reported [3].

We present a case of EAV to D3/D4 junction in a woman in her late 40s diagnosed during intraoperative cholangiogram (IOC) for biliary colic and was successfully treated with cholecystectomy. Informed consent obtained and patient anonymity preserved.

CASE REPORT

A female of middle-eastern background in her late 40s was referred to the surgical specialist outpatient clinic for biliary colic. Her presenting complaint was intermittent postprandial upper abdominal pain. Liver function was normal including bilirubin 7 μmol/L. Abdominal ultrasonography demonstrated fatty liver, 30 mm mobile gallstone, and CBD 5 mm. She was consented for elective laparoscopic cholecystectomy.

Intraoperative findings revealed fatty liver, chronic cholecystitis, thickened gallbladder wall and Callot's triangle, plus wide cystic duct with low insertion. Intraoperative cholangiogram highlighted dilated biliary tree and main pancreatic duct with EAV to D4 without filling defects. The distal bile duct was also associated with a longer common channel (Figure 2). Dissection was otherwise uncomplicated, and the patient was discharged. A postoperative magnetic resonance cholangiopancreatography (MRCP) was obtained to further assess the anatomical region of the ampulla. This again showed biliary-pancreatic duct prominence without visible cause, and EAV to distal D3/proximal D4 (Figure 3). Other findings include a hepatic segment 7 probable hemangioma and a single benign subcapsular hepatic segment 6 cyst. Histopathology confirmed chronic cholecystitis with a single 30 mm gallstone. The patient recovered uneventfully during her follow-up appointment and was discharged from surgical services.

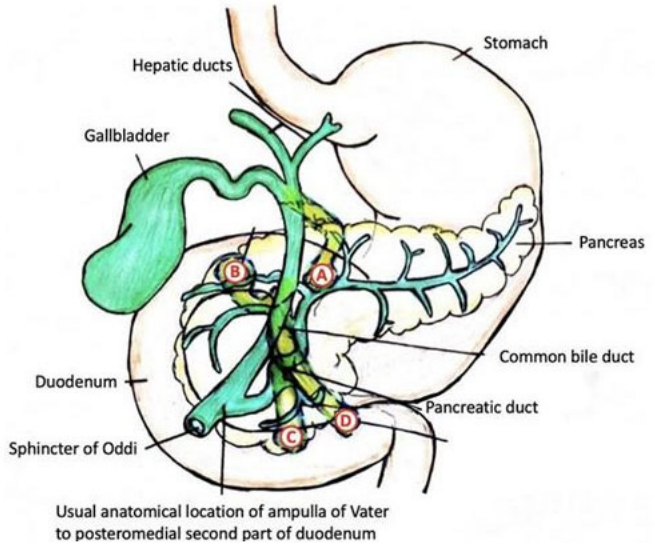

Figure 1: Illustration of the usual anatomy of biliary tree, with commonest locations of ectopic hepatopancreatic ampulla of Vater to (A) pylorus/antrum of stomach, (B) duodenal bulb, (C) third part of duodenum, and (D) fourth part of duodenum. Note that the common bile duct tends to become more hook-shaped in proximal ectopic locations.

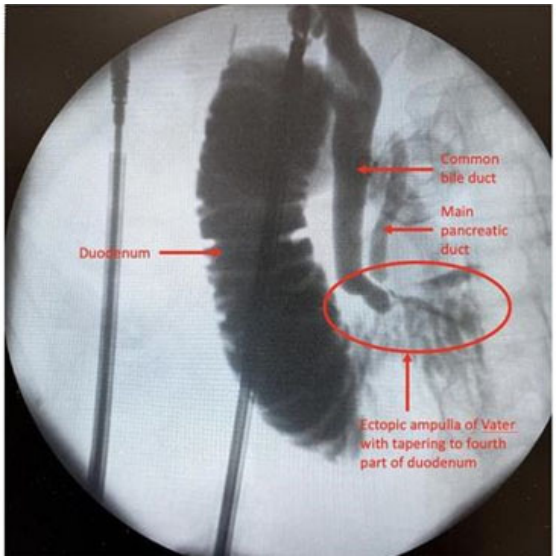

Figure 2: Intraoperative cholangiogram. Dilated biliary tree and main pancreatic duct without filling defects but lack of normal drainage to the posteromedial second part of duodenum. Confluence of common bile duct and main pancreatic duct at ectopic ampulla of Vater with long common channel to ascending fourth part of duodenum.

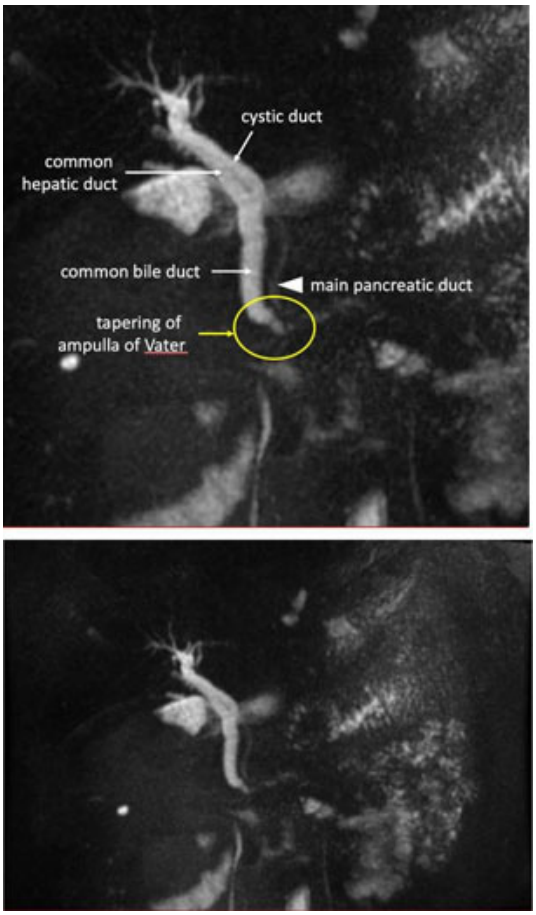

Figure 3: MRCP coronal view demonstrates post-cholecystectomy status, mild pancreatic duct dilation to 3.8 mm (arrowhead) without a visible cause, and extrahepatic biliary dilation (white arrows). The ectopic ampulla empties into distal D3/proximal D4 (yellow arrow and circle).

DISCUSSION

The detection of EAV is influenced by rising rates of endoscopic retrograde cholangiopancreatography (ERCP) and routine IOC during cholecystectomy. The largest study involved over 12,000 patients who underwent ERCP [4]. However, they focused on 1 ectopic site, detecting 53 patients with EAV to duodenal bulb [4]. Another study of 1040 ERCPs by Orhan Segzin et al. encountered ectopic locations into the stomach (0.1%), duodenal bulb (0.38%), lateral D2 (0.29%), and D3 (0.29%) but none into D4 [5]. Detection of EAV into D4 is limited to solitary reports, apart from a study of 107 patients with EAV by Junbo Hong et al., noting 3.7% incidence [1, 3]. Thus, duodenal bulb is the most frequently encountered ectopic location, while D4 is least implicated [3, 5]. Ectopic ampullas of Vater have a preponderance toward elderly males—age ranging from mid-fifties [1, 2, 4]. Most literature originated from Eastern countries and Turkey, suggesting greater incidence in Asians than Westerners.

The etiology for this anomaly has yet been explained, but in theory, it occurs due to disruption of the diverticulum hepaticum from which the biliary tree develops embryologically [4–6]. Premature division of the pars hepatica, the cranial part of diverticulum giving rise to the intrahepatic and common hepatic ducts will result in the bile duct assuming a horizontal position proximally into the stomach [4–6].

Ectopic ampullas of Vater are almost always associated with congenital biliary dilatation, with an exception of 1 patient discovered incidentally during workup of diarrhea [4]. Pancreatic dilatation was noted in 26% of visualized ducts—6 out of 23 recorded in literature [4]. Sphincteric function may sometimes be intact but otherwise more commonly compromised with free-flow duodenobiliary and biliary reflux proximally into duodenal bulb, noting duodenal contents into biliary tree accounting for development of cholangitis, and the latter insult causing duodenal ulceration which may progress into stenosis, deformity, and obstruction [4, 5]. As a result, pneumobilia may be noted on imaging or through fluoroscopy during ERCP [4].

Ectopic ampullas of Vater to the duodenal bulb often present with intractable duodenal ulcer disease and are associated with other pancreaticobiliary disorders such as pancreatitis, choledocholithiasis, and acute cholangitis [1, 2, 5–7]. Bile duct stenosis has also been reported, commonly located in the distal CBD [1, 4]. Moreover, duodenal obstruction may complicate worsening duodenal stenosis [4]. Extreme care is cautioned with surgery, with a simple gastroenterostomy bypass preferred to more complex surgeries involving the biliary system such as Bilroth I and II to avoid potentially fatal bile duct injuries [4]. Ectopic ampullas of Vater proximal to their usual location to D2 (stomach, duodenal bulb) develop these symptoms due to tapered narrowing and hooked distal end of CBD resulting in a dilated extrahepatic bile duct, bile-stained papilla in the bulb orifice, all of which can be detected either endoscopically or radiographically [1, 6, 7].

This rare congenital anomaly has scarce reports on the detection of EAVs to D3 and D4 [3, 8]. Up until our patient, there are only 6 reported cases of ectopic drainage to D4, with 2 each by papers dated 1985 (Doty et al.) and 1991 (Kafruni et al.) respectively, one case in 1989 (McQuillan, Castles) and the more recent case by Jin et al. in 2009 [3, 8]. This places emphasis on the rarity of our patient's EAV especially to D3/D4 junction and the limited literature to fully implicate the perioperative risks and long-term sequelae of this anomaly. The 1 patient Orhan Segzin et al. encountered with EAV into D3 was unable to be cannulated by ERCP due to inability to obtain appropriate angulation [5].

On top of that, the patient reported by Jin et al. was a 71-year-old woman who presented with concomitant periampullary cancer which has yet to be described again in association with EAVs [3]. As the patient was unfit for endoscopic ampullectomy, a choledochojejunostomy was performed [3]. In the older publications, surgical intervention was also required for all patients, namely choledochoenteric anastomosis for 2 school-aged children described by Doty et al. (1985), plus transduodenal sphincteroplasty and laparotomy with Kehr's T-tube choledostomy respectively for women aged 29 and 39 years recounted by Kafruni et al. (1991) [3]. In contrast, our patient in her late forties became symptom-free after an uneventful cholecystectomy not requiring additional interventions, the first to be defined.

There are several methods to detect EAVs. Magnetic resonance cholangiopancreatography is the most reliable imaging tool to further delineate findings from computed tomography (CT) and procedures undertaken [8, 9]. Other modalities include percutaneous transhepatic cholangiography and upper gastrointestinal endoscopy [9]. Jin et al. demonstrated that preoperative MRCP was beneficial in displaying not only the ectopic drainage to D4, but also excluded associated anomalies of the biliary tree and pancreatic duct [3]. Such occurrence can also be depicted in Yasuo et al.'s case of a double CBD with ectopic drainage to the lesser curvature of the stomach by MRCP [8]. Whereas in our case, MRCP confirmed the location of ectopic ampulla postoperatively after initial detection via IOC. Comparably, IOC during cholecystectomy excellently visualize variant anatomy of the biliary tree [10]. EAVs is associated with dilated biliary tree, angulated hook-shaped CBD, and distorted duodenum—increasing the complexity of ERCPs, and sphincterotomy is limited due to risk of perforation and bleeding [10].

Endoscopic retrograde cholangiopancreatography remains the gold standard choice that is both diagnostic and therapeutic [1, 2]. Stone extraction is commonly performed via papillary balloon dilatation for choledocholithiasis, but stenting preferred in comorbid and/or elderly patients [4]. This seemed to be a safer alternative to sphincterotomy, which is limited by higher rates of perforation and bleeding [4, 11]. As EAVs are

associated with dilated biliary tree, angulated hook-shaped CBD and distorted duodenum, the complexity of ERCPs are amplified [1, 8]. The ectopic opening is obscured in majority of cases, making identification and cannulation challenging [1]. Cannulation is successful in 83.2% (Hong et al.) and 96% (Disibeyaz et al.) of patients with greatest failure rate in ampullas to the duodenal bulbar descending junctions, due to duodenal deformity or stenosis [1]. Cannulation was achieved in 22.6% of patients only after duodenal bulb dilation in Disibeyaz et al.'s article [4]. Stone extraction is limited by stone sizes 1 cm or greater, presence of 2 or more stones and duodenal stenosis [1]. Patients with EAVs are also at increased risk of ERCP complications of pancreatitis, hyperamylasemia and biliary infections [1]. Note that several patients represented with recurrent choledocholithiasis and cholangitis after ERCP [4]. Nonetheless, ERCP treats most pathologies associated with EAVs. This may be followed by elective surgical therapy or vice versa. Surgery is opted after failed ERCP, although patients without choledocholithiasis could potentially be treated medically [4]. Surgery was the mainstay treatment in the past due to fear of bleeding and perforation via endoscopic sphincterotomy; however, this is overcome by safer techniques such as balloon dilatation [4].

Endoscopic ultrasound (EUS) is less invasive than ERCP [12]. It is said to have a negligible rate of complications [12]. However, the use of EUS only been described in 1 study demonstrating its use in the detection of EAV into duodenal bulb, and rarely mentioned in studies [2, 5, 12]. Despite views of a dilated CBD, choledocholithiasis and anomalous drainage into duodenal bulb, final diagnosis was still confirmed with direct visualization and fluoroscopy during ERCP [12]. Cannulation was technically challenging, and ultimately the patient underwent cholecystectomy, CBD exploration and extraction of stones and choledochoenterostomy [12].

Note that multiple pathologies can be at play in patients with EAV. These may overshadow one another and be unresolved or partially treated. Disibeyaz et al. found 64% of patients diagnosed with EAVs had previous cholecystectomy, demonstrating that despite cholecystectomy, these patients are likely to present with complications or concomitant pathologies requiring further management [4]. Complications include symptoms of recurrent stone pathology—biliary colic and obstructive patterns of raised cholestatic enzymes, cholangitis, jaundice, and/or dilated biliary tree on imaging—whereas possible concomitant pathologies are ulcers of the stomach and/or duodenum, and duodenal stenosis [4]. Knowledge of anatomical variants and their associated complications can aid surgeons in linking these as the cause for patient's symptoms and avoid complications, namely bile peritonitis, abscess, fistula, and ductal strictures during CBD exploration or sphincterotomy [6, 7].

CONCLUSION

Intraoperative cholangiogram is useful in detecting biliary anomalies; however, the gold standard for diagnosing ectopic bile ducts is via ERCP. Knowledge of anatomical variants aids perioperative planning and minimizes complications. Hepatobiliary anatomical variants can also occur in the location of the ampulla, thus it is important for surgeons and trainees to interpret and document the location of ampulla in operative reports carefully during intraoperative cholangiogram, especially in patients who may require endoscopic retrograde cholangiopancreatography in the perioperative period and/or later date. The patient should be educated to seek medical attention if symptoms persist or recur, despite being post-cholecystectomy and/or post-ERCP.

REFERENCES

1. Hong J, Pan W, Zuo W, et al. Efficacy and safety of therapeutic ERCP in patients with ectopic papilla of Vater. Medicine (Baltimore) 2020;99(1):e18536.
2. Köklü S, Kekilli M, Arhan M, Demirel HA, Dadasov M, Yüksel O. A congenital anomaly as a cause of abdominal pain in a 74-year-old man. J Am Geriatr Soc 2009;57(9):1728–9.
3. Jin SG, Chen ZY, Yan LN, Zeng Y, Huang W, Xu N. A rare case of periampullary carcinoma with ectopic ending of Vater's ampulla. World J Gastroenterol 2009;15(37):4729–31.
4. Disibeyaz S, Parlak E, Cicek B, et al. Anomalous opening of the common bile duct into the duodenal bulb: Endoscopic treatment. BMC Gastroenterol 2007;7:26.
5. Sezgin O, Altintaş E, Uçbilek E. Ectopic opening of the common bile duct into various sites of the upper digestive tract: A case series. Gastrointest Endosc 2010;72(1):198–203.
6. Lee SS, Kim MH, Lee SK, et al. Ectopic opening of the common bile duct in the duodenal bulb: Clinical implications. Gastrointest Endosc 2003;57(6):679–82.
7. Lee HJ, Ha HK, Kim MH, et al. ERCP and CT findings of ectopic drainage of the common bile duct into the duodenal bulb. AJR Am J Roentgenol 1997;169(2):517–20.
8. Amano Y, Takahashi M, Oishi T, Kumazaki T. MR cholangiopancreatography of double common bile duct with ectopic drainage into stomach. J Comput Assist Tomogr 2002;26(1):141–2.
9. Nasseri-Moghaddam S, Nokhbeh-Zaeem H, Soroush Z, Bani-Solaiman Sheybani S, Mazloum M. Ectopic location of the ampulla of vater within the pyloric channel. Middle East J Dig Dis 2011;3(1):56–8.
10. Elkerkary M, Ellabban G, Shams M, Abdel-Raheem M, Shaban H, Hassan A. Comparison between laparoscopic ultrasound and intraoperative cholangiogram in detection of common bile duct stones during laparoscopic cholecystectomy for cholelithiasis: A prospective study. World J Lap Surg 2021;14(2):69–74.

11. Kobayashi K, Murayama M, Sugasawa H, Nishikawa M, Nishiyama K, Takeo H. Duodenal stenosis associated with an ectopic opening of the common bile duct into the duodenal bulb: A case report. Surg Case Rep 2021;7(1):257.
12. Krstic M, Stimec B, Krstic R, Ugljesic M, Knezevic S, Jovanovic I. EUS diagnosis of ectopic opening of the common bile duct in the duodenal bulb: A case report. World J Gastroenterol 2005;11(32):5068–71.

****

Author Contributions

Xin Yi Goai – Conception of the work, Design of the work, Acquisition of data, Analysis of data, Interpretation of data, Drafting the work, Revising the work critically for important intellectual content, Final approval of the version to be published, Agree to be accountable for all aspects of the work in ensuring that questions related to the accuracy or integrity of any part of the work are appropriately investigated and resolved

Michelle Min Hsiao – Acquisition of data, Analysis of data, Interpretation of data, Drafting the work, Revising the work critically for important intellectual content, Final approval of the version to be published, Agree to be accountable for all aspects of the work in ensuring that questions related to the accuracy or integrity of any part of the work are appropriately investigated and resolved

Mohamed Ashour – Conception of the work, Design of the work, Analysis of data, Interpretation of data, Revising the work critically for important intellectual content, Final approval of the version to be published, Agree to be accountable for all aspects of the work in ensuring that questions related to the accuracy or integrity of any part of the work are appropriately investigated and resolved

Guarantor of Submission

The corresponding author is the guarantor of submission.

Source of Support

None.

Consent Statement

Written informed consent was obtained from the patient for publication of this article.

Conflict of Interest

Authors declare no conflict of interest.

Data Availability

All relevant data are within the paper and its Supporting Information files.