

CASE REPORT

PEER REVIEWED | OPEN ACCESS

An incidental finding of a pseudocoarctation of the aorta in a trauma patient: A case report and literature review

Fatima Alharmoodi, Shadin Ghabra, Salwa Alrumaithi,
Maysam Abu Sa'a, Suleiman Shantour

ABSTRACT

Introduction: Pseudocoarctation is an uncommon anomaly with different presentations that is primarily discovered with other abnormalities. Management is required with symptomatic patients.

Case Report: In this paper we discuss a patient who was diagnosed incidentally and treated conservatively, followed by a brief literature review and discussion.

Conclusion: Depending on the symptoms, surgical treatment with follow-up might be indicated.

Keywords: Aorta, Echo, Pseudocoarctation

INTRODUCTION

Pseudocoarctation of the aorta is an anomaly seen with hypoplastic aortic arch conditions and is under the similar disease spectrum. This condition is mainly seen in pediatric age groups. This can be misdiagnosed as the more commonly known lesion of cortication of the aorta, adding unnecessary investigations and a cost burden. Other congenital anomalies such as a ventricular septal defect and tetralogy of Fallot have both been associated with pseudocoarctation of aorta [1]. Clinical symptoms may be absent at the time of diagnosis. In this case report we present an incidental finding of a pseudocoarctation of the aorta in a trauma patient with hypertension that was managed conservatively.

CASE REPORT

A 42-year-old male patient, with a past medical history of hypertension on lisinopril and dyslipidemia on a rosuvastatin, presented to the emergency department after a motor vehicle collision (MVC). He was a pedestrian hit by car. The primary survey was unremarkable except for a closed left fibula fracture. The secondary survey revealed facial lacerations. He denied abdominal pain and chest pain. The patient was taken for a trauma computed topography (CT) scan that included head, neck, spine, chest, abdomen, and pelvis. The CT scan was unremarkable except for an incidental congenital finding of kinking of the descending thoracic aorta which is in favor of pseudocoarctation of the aorta (Figure 1). He was admitted for observation and pain control. The facial lacerations were sutured with Prolen 4-0. A cardiology consultation was obtained and echocardiogram was performed. The echocardiogram showed an ejection fraction of 82%, a discrete stenosis of the aorta just distal to the origin of left subclavian artery with gradient of 45/23 mmHg consistent with the diagnosis (Figure 2). No sign of aortic stenosis or any other cardiac abnormalities were seen otherwise. The case was discussed with the cardiologist after the report of the echocardiogram. No intervention was decided. However, the recommendations were to continue with his

How to cite this article

Alharmoodi F, Ghabra S, Alrumaithi S, Abu Sa'a M, Shantour S. An incidental finding of a pseudocoarctation of the aorta in a trauma patient: A case report and literature review. J Case Rep Images Surg 2024;10(1):30–33.

Article ID: 100134Z12FA2024

doi: 10.5348/100134Z12FA2024CR

Fatima Alharmoodi¹, Shadin Ghabra², Salwa Alrumaithi¹,
Maysam Abu Sa'a³, Suleiman Shantour¹

Affiliations: ¹Department of General Surgery, Tawam Hospital, Al Ain, UAE; ²Department of General Surgery, Medstar Georgetown University Hospital, Washington D.C., USA; ³Department of Radiology, Tawam Hospital, Al Ain, UAE.

Corresponding Author: Fatima Alharmoodi, Department of General Surgery, Tawam Hospital, Al Ain, UAE; Email: harmoodi.f@gmail.com

Received: 23 January 2024

Accepted: 01 March 2024

Published: 18 March 2024

home medication of an angiotensin converting enzyme inhibitor and a statin. The patient was subsequently discharged from the hospital for follow-up in the clinic.

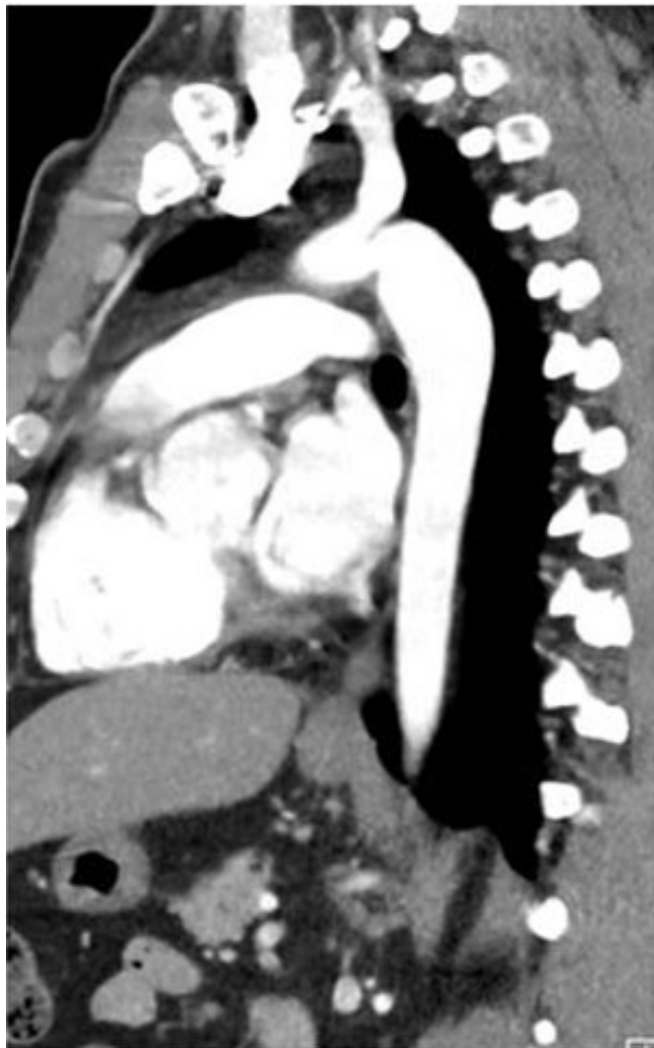

Figure 1: CT demonstrating kinking in the descending thoracic aorta, indicating pseudocoarctation of the aorta.

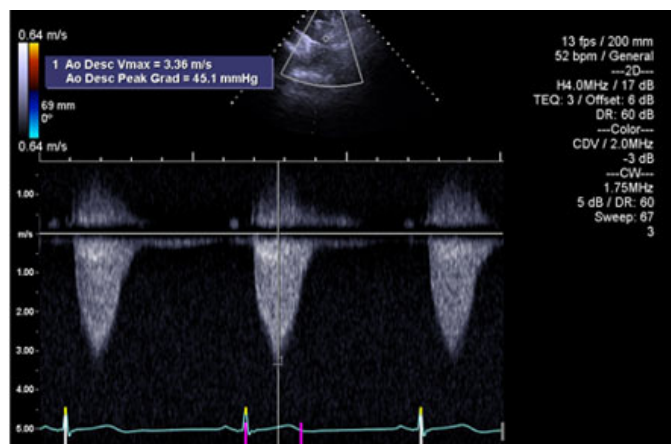


Figure 2: Echocardiogram confirming the diagnosis of pseudocoarctation of aorta with gradient of 45/23 mmHg.

DISCUSSION

Pseudocoarctation of the aorta is a rare congenital anomaly that might be associated with other abnormalities like ventricular septal defect (VSD), aortic stenosis, bicuspid aortic valve, and other cardiac abnormalities [1]. It is described as kinking and narrowing of the aortic arch without causing obstruction [2].

The majority of the cases reported were diagnosed incidentally or via the recognition of other symptoms like hypertension or due to compression of surrounding structures. Symptomatic patients may present with chest pain, dysphagia, or signs of Horner's syndrome [3]. One theory behind this condition goes back to the embryological development of the aortic arch. The compression of the third over the seventh dorsal segment is less than normal, resulting in a longer aortic arch that kinks at the level of ductus arteriosus [4].

The initial method of diagnosis should include an echocardiogram and a CT angiography to rule out other abnormalities and to verify the presence of the pseudocoarctation versus an actual coarctation of the aorta [4]. Other authors recommend a magnetic resonance angiography (MRA) for diagnosis and follow-up.

As it was suggested by Gay et al., the criteria to diagnose pseudocoarctation of aorta include a small or absent gradient of less than 25 mmHg, no increase in the collateral vessels, an abnormal roentgenogram, and a definitive aortogram to confirm the diagnosis [5]. The treatment of pseudocoarctation will depend on the presence or absence of any symptoms. If patients are symptomatic, surgical intervention is preferred especially with the presence of aortic aneurysm. Alternatively, patients can be treated conservatively when symptoms are lacking [3, 6].

A pseudocoarctation of aorta can lead to an aortic aneurysm due to the increase in the turbulent blood flow in the post-stenotic part of the aorta [7]. In these cases, the surgical treatment of choice is excision of the aneurysmal part of the aorta, and a close annual follow-up [8]. Other surgical options include a replacement of the ascending aorta and a prosthetic aortic valve replacement [3]. A case report by Shafaghi et al. was published about a young patient who had aortic aneurysm with an incidental finding of a pseudocoarctation post-trauma. The patient developed a massive hemothorax and underwent a left sided thoracotomy with excision of the aneurysmal part and an interposition graft insertion [9]. Therefore, it is essential for patients with a pseudocoarctation to be careful with their daily activities and avoid certain type of sports that might cause rupture of the aorta.

In the past years, the preferred method for treating coarctation of aorta was with the use of balloon angioplasty, which showed a high rate of recurrence, hence it is now combined with stenting the aorta [10]. From this approach, angioplasty and stent placement are considered another treatment option for patients with pseudocoarctation of aorta [11].

CONCLUSION

Pseudocoarctation of aorta is a rare congenital anomaly that might present with other abnormalities. It is discovered incidentally in asymptomatic patients who are managed conservatively. Other times, it presents with symptoms that might require surgical intervention to cure. Close annual follow-up with imaging modalities like CT angiography or MRA is required.

REFERENCES

1. Adaletli I, Kurugoglu S, Davutoglu V, Ozer H, Besirli K, Sayin AG. Pseudocoarctation. *Can J Cardiol* 2007;23(8):675–6.
2. Son JS, Hong KB, Chung DC. Pseudocoarctation of the aorta associated with the anomalous origin of the left vertebral artery: A case report. *Korean J Radiol* 2008;9(3):283–5.
3. Cordeiro F, Silva Carvalho S, Ferreira A, Moreira JJ. Aortic pseudocoarctation: A very rare finding. *BMJ Case Rep* 2018;2018:bcr2017222924.
4. Singh S, Hakim FA, Sharma A, et al. Hypoplasia, pseudocoarctation and coarctation of the aorta – A systematic review. *Heart Lung Circ* 2015;24(2):110–8.
5. Gay WA Jr, Young WG Jr. Pseudocoarctation of the aorta. A reappraisal. *J Thorac Cardiovasc Surg* 1969;58(5):739–45.
6. Kessler RM, Miller KB, Pett S, Wernly JA. Pseudocoarctation of the aorta presenting as a mediastinal mass with dysphagia. *Ann Thorac Surg* 1993;55(4):1003–5.
7. Makani S, Mitchell J, Metton O, Di Filippo S, Henaine R, Ninet J. Surgical repair of a pseudocoarctation with cervical aortic arch complicated by multiple aneurysms of the aorta: A case report. *Pan Afr Med J* 2017;26:236.
8. Sasaki Y, Suehiro S, Shibata T, Minamimura H, Hattori K, Kinoshita H. Case of pseudocoarctation associated with aneurysm of the descending aorta. [Article in Japanese]. *Nihon Kyobu Geka Gakkai Zasshi* 1995;43(6):898–902.
9. Shafaghi S, Behzadnia N, Sharif-Kashani B, Naghashzadeh F, Ahmadi ZH. Traumatic transection of descending thoracic aorta presenting as pseudocoarctation. *Tanaffos* 2018;17(4):295–8.
10. Forbes TJ, Gowda ST. Intravascular stent therapy for coarctation of the aorta. *Methodist Debaque Cardiovasc J* 2014;10(2):82–7.
11. Gimenez-Roqueplo AP, Tomkiewicz E, La Batide-Alanore A, et al. Stent treatment for pseudocoarctation and refractory hypertension in an elderly patient with Takayasu's arteritis. *Nephrol Dial Transplant* 2000;15(4):536–8.

Author Contributions

Fatima Alharmoodi – Conception of the work, Design of the work, Acquisition of data, Analysis of data, Interpretation of data, Drafting the work, Revising the work critically for important intellectual content, Final approval of the version to be published, Agree to be accountable for all aspects of the work in ensuring that questions related to the accuracy or integrity of any part of the work are appropriately investigated and resolved

Shadin Ghabra – Conception of the work, Design of the work, Acquisition of data, Analysis of data, Interpretation of data, Drafting the work, Revising the work critically for important intellectual content, Final approval of the version to be published, Agree to be accountable for all aspects of the work in ensuring that questions related to the accuracy or integrity of any part of the work are appropriately investigated and resolved

Salwa Alrumaithi – Conception of the work, Design of the work, Acquisition of data, Analysis of data, Interpretation of data, Drafting the work, Revising the work critically for important intellectual content, Final approval of the version to be published, Agree to be accountable for all aspects of the work in ensuring that questions related to the accuracy or integrity of any part of the work are appropriately investigated and resolved

Maysam Abu Sa'a – Conception of the work, Design of the work, Acquisition of data, Analysis of data, Interpretation of data, Drafting the work, Revising the work critically for important intellectual content, Final approval of the version to be published, Agree to be accountable for all aspects of the work in ensuring that questions related to the accuracy or integrity of any part of the work are appropriately investigated and resolved

Suleiman Shantour – Conception of the work, Design of the work, Acquisition of data, Analysis of data, Interpretation of data, Drafting the work, Revising the work critically for important intellectual content, Final approval of the version to be published, Agree to be accountable for all aspects of the work in ensuring that questions related to the accuracy or integrity of any part of the work are appropriately investigated and resolved

Guarantor of Submission

The corresponding author is the guarantor of submission.

Source of Support

None.

Consent Statement

Written informed consent was obtained from the patient for publication of this article.

Conflict of Interest

Authors declare no conflict of interest.

Data Availability

All relevant data are within the paper and its Supporting Information files.

Copyright

© 2024 Fatima Alharmoodi et al. This article is distributed under the terms of Creative Commons Attribution License which permits unrestricted use, distribution and reproduction in any medium provided the original author(s) and original publisher are properly credited. Please see the copyright policy on the journal website for more information.

Access full text article on
other devices



Access PDF of article on
other devices





INTERNATIONAL JOURNAL OF
CASE REPORTS AND IMAGES



VIDEO JOURNAL OF
CLINICAL RESEARCH



VIDEO JOURNAL OF
BIOMEDICAL SCIENCE




INTERNATIONAL JOURNAL OF
HEPATOBIILIARY AND
PANCREATIC DISEASES



INTERNATIONAL JOURNAL OF
BLOOD TRANSFUSION AND
IMMUNOHEMATOLOGY



EDORIUM JOURNAL OF
OPHTHALMOLOGY



EDORIUM JOURNAL OF
MEDICINE



EDORIUM JOURNAL OF
CARDIOTHORACIC AND
VASCULAR SURGERY



JOURNAL OF CASE REPORTS
AND IMAGES IN ORTHOPEDICS
AND RHEUMATOLOGY



EDORIUM JOURNAL OF
PSYCHOLOGY



EDORIUM JOURNAL OF
CELL BIOLOGY



JOURNAL OF CASE REPORTS AND IMAGES IN
DENTISTRY



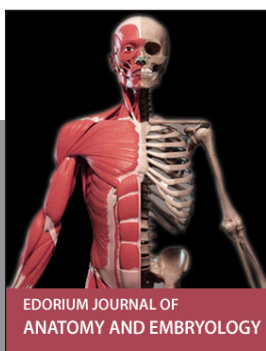
EDORIUM JOURNAL OF
CANCER



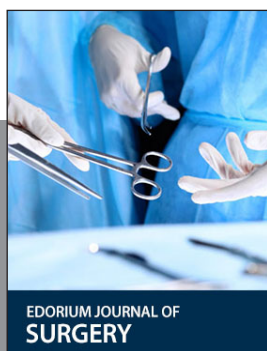
EDORIUM JOURNAL OF
PSYCHIATRY



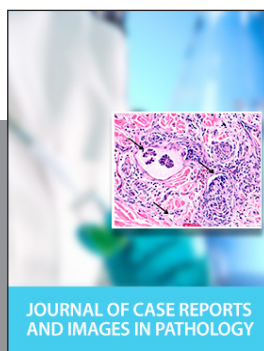JOURNAL OF CASE REPORTS AND
IMAGES IN INFECTIOUS DISEASES



EDORIUM JOURNAL OF
ANATOMY AND EMBRYOLOGY



EDORIUM JOURNAL OF
SURGERY



JOURNAL OF CASE REPORTS
AND IMAGES IN PATHOLOGY



EDORIUM JOURNAL OF
ANESTHESIA